


**PRESENTING CLINICAL SIGNS**

**DATE** History: Grade 6/6 murmur. Coughing, syncope, delirium. Receiving furosemide 20 mg BID.

**ECHOCARDIOGRAPHIC FINDINGS**

2D, M-mode, and Doppler study.

**PERFORMED BY:**

Sarah Pender, CVT

**INTERPRETED BY**

Keith Blass, DVM,  
MS, DACVIM  
(Cardiology)

There is moderate left atrial dilation. The mitral valve leaflets are thickened and exhibit systolic prolapse. A moderate to severe jet of eccentric mitral regurgitation is present. There is mild left ventricular dilation. Left ventricular systolic function is hyperdynamic. The aorta and aortic valve are normal. Right atrial and right ventricular dimensions are normal. The tricuspid valve leaflets are mildly thickened, and a mild jet of tricuspid regurgitation is present. TR velocity is consistent with the presence of moderate pulmonary hypertension (PG 73.8 mmHg). The pulmonary artery and pulmonic valve are normal. No pericardial effusion or cardiac masses are seen.

LA - 39.8 mm  
LVIDd - 32.0 mm  
LVIDs - 17.1 mm  
FS - 46.5%  
RA - 25.0 mm  
LVOT - 1.12 m/s  
RVOT - 0.49 m/s  
TR - 4.29 m/s

**PATIENT**

Zoom Zoom  
Niermann

**SPECIES**

Canine

**ASSESSMENT/RECOMMENDATIONS**

Degenerative mitral and tricuspid valve disease  
Pulmonary hypertension

**BREED**

Jack Russell

This examination demonstrates regurgitation of blood across Zoom Zoom's mitral and tricuspid valves resulting from degenerative valve disease. Zoom Zoom's tricuspid valve disease is mild, as evidenced by his absence of secondary right heart chamber dilation. His mitral valve disease is more advanced, as Zoom Zoom has moderate to severe mitral regurgitation present, with moderate secondary dilation of his left atrium and mild dilation of his left ventricle, as well as moderate secondary pulmonary hypertension. Given the presence of moderate left atrial dilation, it's possible that mainstem bronchial compression could be contributing to Zoom Zoom's cough, though thoracic radiographs are recommended for further evaluation. Zoom Zoom's pulmonary hypertension is likely the cause of his syncopal episodes, and his disease also puts him at risk for the development of exercise intolerance and right-sided congestive heart failure.

**SEX**

MN

**AGE**

16 y

I recommend adding pimobendan (2.5 mg BID) and sildenafil (20 mg BID-TID) to Zoom Zoom's current therapy with furosemide, as the former should help to slow the progression of his mitral valve disease, while the latter will treat his pulmonary hypertension. A cough suppressant, such as hydrocodone, may be given if Zoom Zoom's cough persists.

**WEIGHT**

21 lb

A focused echocardiogram to reevaluate the severity of Zoom Zoom's pulmonary hypertension in response to therapy is recommended in 1 month.

**HOSPITAL NAME**

SVS Imaging QC

**REFERRING VET**

Dr. Shannon



DATE

4/21/22

PERFORMED BY:

Sarah Pender, CVT

INTERPRETED BY

Keith Blass, DVM,  
MS, DACVIM  
(Cardiology)

PATIENT

Zoom Zoom  
Niermann

SPECIES

Canine

BREED

Jack Russell

SEX

MN

AGE

16 y

WEIGHT

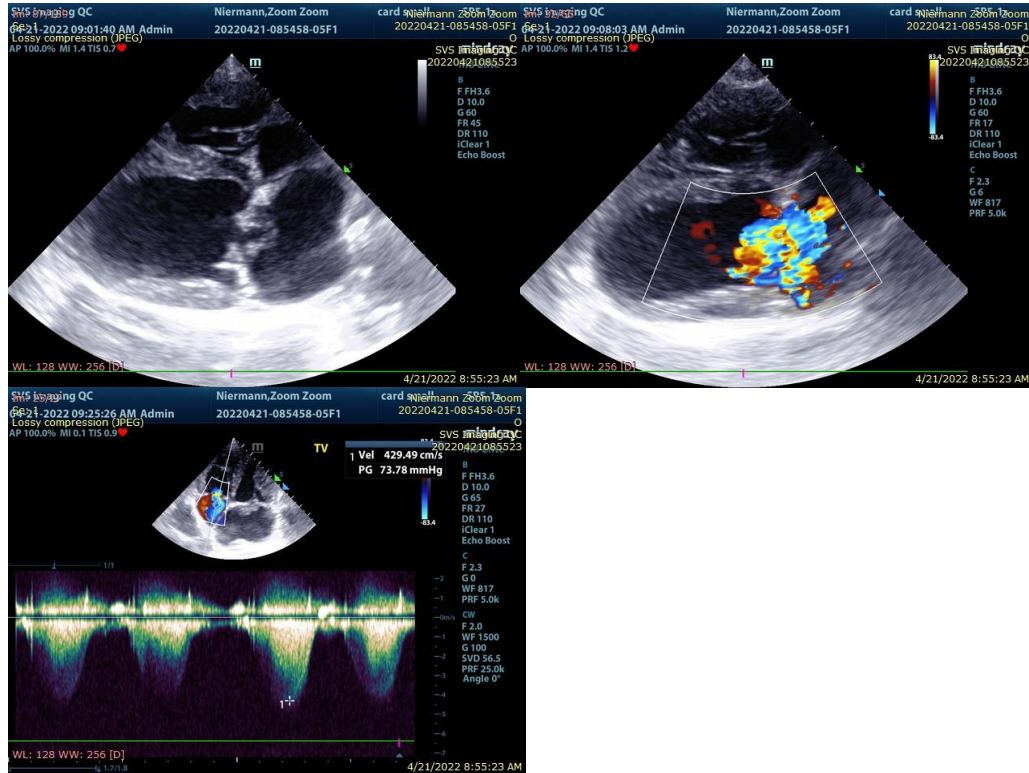
21 lb

HOSPITAL NAME

SVS Imaging QC

REFERRING VET

Dr. Shannon



The information and recommendations provided are based on the images presented by the referring veterinarian. No evaluation can be communicated regarding pathology that was not visible in the image/video clips provided.

Thank you for this referral. If the clinical or image interpretation does not parallel your findings or if I can be of any further assistance please contact me.

Keith Blass, DVM, MS, DACVIM (Cardiology)  
KeithBlass@gmail.com  
631-804-5754